

ALL-INSIDE SUTURE TECHNIQUE FOR PALMER CLASS 1B TRIANGULAR FIBROCARILAGE REPAIR

L.A. PEDERZINI, M. TOSI, M. PRANDINI, C. BOTTICELLA, L. MILANDRI

Arthroscopic and Sport Medical Center, New Sassuolo Hospital

SUMMARY

Introduction: *Current techniques for TFCC 1B lesions do not completely avoid residual ulnar pain due to the knot positioned in the subcutaneous tissue.* **Materials and methods:** *A slotted needle allows to position a loop extrarticularly and the knot intrarticularly.* **Outcomes:** *This seems to avoid completely residual ulnar pain and allows a better stability.* **Conclusions:** *This technique permits to have a good repair and healing of 1B TFCC lesions.* Riv Chir Mano 2006; 3: 367-369

KEY WORDS

TFCC, needle, knot, wrist

INTRODUCTION

The treatment of TFCC lesions is in relationship to the location and the age of the patient. The blood supply is limited at 10-40% of the outskirts, while the central portion is completely avascular. Over time, the biomechanical validity of TFCC reinsertion has led to the publication of various studies on arthroscopic suture techniques (1). Bednar and Ostermann (2) cite the use of K-wire for the repair of radial tears. Poehling (3) cites the inside-out technique, while other authors such as Whipple (4) or Hempfling (5), prefer to use the outside-in technique typical of meniscal repairs. More recently, Bohringer, introduced the use of all-inside meniscal suturing (double T Mitek anchor and meniscal fastener), while Whatley and Arnoczky (6) demonstrated the possibility of TFCC regeneration on animals using fibrin clots. It is clear then, that it is necessary to suture the TFCC in a different way for tears that involve well-vascularised areas (Palmer 1B). Debridement for central and radial tears and arthroscopic suturing for ul-

nar-sided tears are still the preferred methods of treatment. The outside-in and inside-out methods described above both involve small extra-articular incisions that allow the isolation of the sensitive branch of the ulnar nerve, a possible cause of neurological complications during suturing (7-8). Long-term results using the outside-in and inside-out methods are good as regards the repair of TFCC, but frequently patients complain of residual ulnar pain for some months, due to the fixing of the knot (impingement) to the floor of the extensor carpi ulnaris tendon sheath (9). Therefore, it is true to say that extra-articular suture fixing does not always guarantee adequate stability for palpation and may require an extra suture.

MATERIALS AND METHODS

The portals normally used are 3-4 and 6R. Once the diagnostic procedure is complete and the ulnar-sided tear has been identified, tear debridement is performed to increase blood supply to the edges of

the tear for adequate healing. A small incision of 1.5 cm is then made to isolate the sensitive branch of the ulnar nerve. Keeping the optic in the 3-4 portal, a slotted needle (Arthrocare Inc. U.K.) is inserted through the capsule wall avoiding the isolated sensitive ulnar branch to penetrate the ulnar-sided TFCC tear. A 2/0 PDS monofilament is then inserted into the needle and once visualised in the joint is withdrawn from the joint through the 6R portal at the back (Fig. 1). At this point, the specific design of the needle allows it to be removed. The same needle is then inserted through the tear at about 0.5 cm from the point where the needle exited on the previous suture. The other end of the suture is inserted into the needle and once visualised is withdrawn through the 6R portal (Fig. 2). In this way, we create an extra-articular loop and both ends of the same suture pass through the tear via the 6R portal. A knot is then tied and fixed inside the joint on the ulnar-sided edge of the TFCC using a pusher. Any excess suture is then cut with a basket punch (Fig. 3). At the end of the operation, the forearm is put into a splint for 25 days.

CONCLUSION

In the past, some authors showed the possibility of suturing traumatic TFCC tears using the open

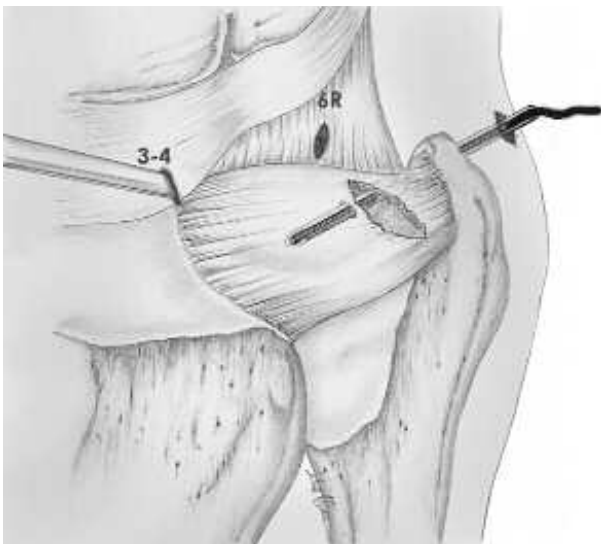


Figura 1

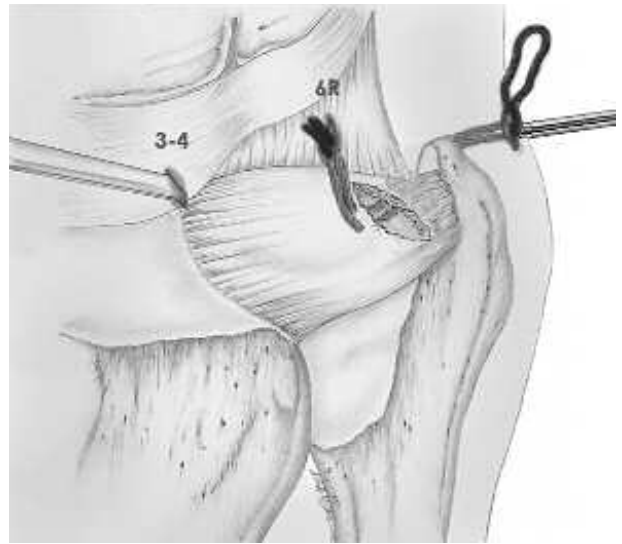


Figura 2

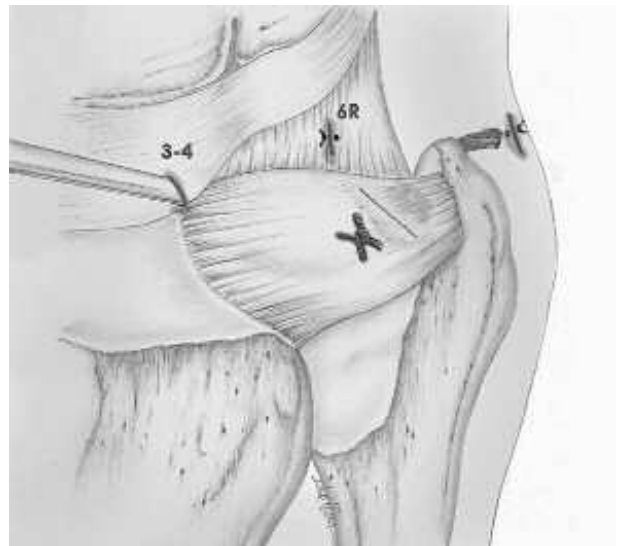


Figura 3

method with good long-term results. For Palmer 1B tears, first Whipple and Hempfling and then Poehling published studies on suture methods, the outside-in and inside-out methods respectively. Although these methods produce very good long-term results, they have also caused problems: residual ulnar pain from the subcutaneous knot on the floor of the extensor carpi ulnaris tendon sheath and in some cases reduced suture holding strength. For the former problem, it was necessary in some cases to re-

move the knot under local anaesthetic three months post-op, whilst in the latter case the insertion of further sutures was recommended to guarantee the stability of the weak suture. The technique presented here, has been performed in the last three years in more than 50 cases of 1B TFCC lesions. The results are extremely encouraging and a 12 months follow-up show Dash score between 0 and 10 points in 85% of the cases. The technique allows to obtain a stable suture with good holding strength for palpation and, as there is no subcutaneous knot, does not cause any pain to arise from the knot irritating the tissue. Moreover, the stability of the suture prevents patients undergoing long periods of immobility and, in any case, never of the elbow.

REFERENCES

1. Whipple TL. Clinical application of wrist arthroscopy. In Lichtman DM (ed): The wrist and its disorders. WB Saunders, Philadelphia 1988; 118-28.
2. Ostermann AL. Arthroscopic debridement of triangular fibrocartilage complex tears. *Arthroscopy* 1990; 6: 120-4.
3. Poehling GC, Siegel DB, Coman LA, Chabon SJ. Arthroscopy of the wrist and elbow. In Green DB (ed): *Operative Hand Surgery*, 3rd edn. Churchill Livingstone, 1993 New York, 189-214.
4. Whipple TL. The role of arthroscopy in the treatment of wrist injuries in the athlete. *Clin Sports Medicine* 1992; 11: 227-38.
5. Hempfling H, Bauer K, Beickert R. Chirurgia artroscopica delle lesioni del legamento triangolare. In Pederzini L (ed): *Artroscopia di polso*. Milano: Springer, 1999.
6. Whatley J, Dejardin L, Arnoczky S. The effect of an exogenous fibrin clot on the regeneration of the triangular fibrocartilage complex: an *in vivo* experimental study in dogs. *Arthroscopy* 2000; 16: 127-36.
7. Pederzini L, Botticella C, Tosi M, Ghinelli D, Esposito M: *Artroscopia di polso*. In Pederzini L (Ed): Springer, Milano, 1999: 23-37.
8. Del Pinal F, Herrero F, Camara A, San Jose J. Complete avulsion of the distal posterior interosseous nerve during wrist arthroscopy: a possible cause of persistent pain after arthroscopy. *J Hand Surgery* 1999; 24A: 240-2.
9. Slutsky D. Arthroscopic repair of dorsal radiocarpal ligament tears. *Arthroscopy* 2002; 18: E49: 1-6.